

ERCP—Diagnostic Technique

Endoscopic Retrograde Cholangiopancreatography

6

Endoscopic retrograde cholangiopancreatography (ERCP) has many applications in patients with known or suspected biliary and pancreatic diseases. The techniques are complex and carry some risk. Optimal results require teamwork between a skilled endoscopist, trained gastrointestinal (GI) nurse/assistants and interested radiology staff.

The experience needed for training, and to maintain competence thereafter, is such that endoscopists should not all expect to practice ERCP. The therapeutic developments (e.g. sphincterotomy, stenting) have become more important than the purely diagnostic studies. There are risks in performing a diagnostic ERCP in the presence of biliary or pancreatic obstruction without being able to provide immediate endoscopic drainage. Thus, ERCP and its therapeutic applications should be considered together. Training in diagnostic ERCP alone is no longer appropriate.

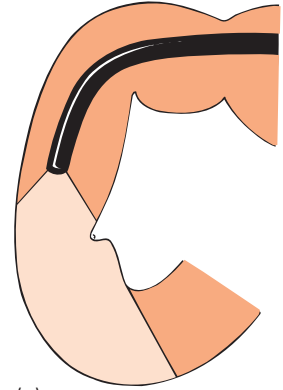
Equipment

Endoscopes

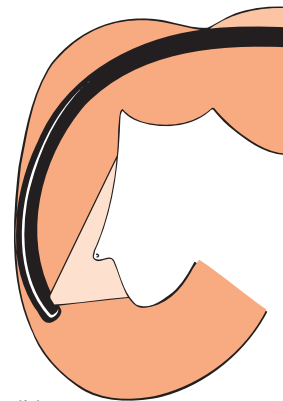
Cannulation is performed with side-viewing instruments. These allow face-on views of the papilla which cannot be achieved with standard forward-viewing endoscopes (Fig. 6.1). There is little to choose between the duodenoscopes of different companies. All have wide-angle lenses to facilitate orientation and a working channel of at least 2.8mm. Endoscopes with larger channels (3.8–4.2mm) are needed for stenting (see Chapter 7), and can be used for *all* ERCP procedures (except in young children). As in other areas, video-endoscopes are supplanting fiberoptic duodenoscopes. Videoscopes provide excellent images and working conditions for ERCP. The slightly longer tip of some first-generation videoscopes was a disadvantage (e.g. when attempting to cannulate from within a diverticulum).

Catheters

Standard catheters are simple Teflon tubes with an outer diameter of at least 5 French gauge (1.7 mm), with distal markings to help judge the depth of insertion (Fig. 6.2). The tip should be slightly rounded and radio-opaque (with metal or special paint) to assist orientation during fluoroscopy. The lumen should be sufficient to allow the passage of a standard 0.035-inch



(a)



(b)

Fig. 6.1 (a) Inadequate view of the papilla with a forward-viewing endoscope . . . (b) . . . and a face-on view with a side-viewer.

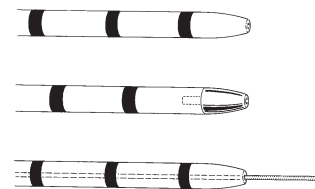


Fig. 6.2 Catheters in routine diagnostic use: standard (above); metal tip (centre); catheter with 0.035-inch guidewire (below).

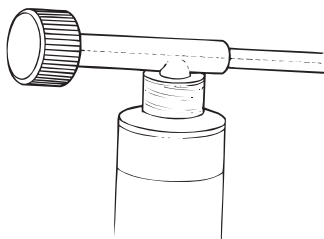


Fig. 6.3 A Luer-Lock syringe attachment to an ERCP catheter with a stiffening stilette.




Fig. 6.4 (a) Short taper catheter.
(b) Very fine taper catheter.

guidewire. The proximal end of the standard catheter has two orifices: one to accommodate a stiffening metal stilette (or guidewire), the other with a Luer fitting at the side for injection of contrast with a syringe (Fig. 6.3).

Innumerable varieties of catheter designs are available, with different sizes, tips and lumens. Double-lumen catheters have the advantage that contrast can be injected relatively easily while maintaining the position with the guidewire. A tip with a short taper (but still a 0.035-inch capable lumen) is often helpful in difficult cases (Fig. 6.4), but very fine tapers (Fig. 6.4) are rarely useful — except at the accessory papilla (see below) — and can easily cause a false passage and some submucosal injection of contrast.

Guidewires

Guidewires are an essential part of diagnostic and therapeutic ERCP. Usually they are 400–480 cm in length to allow complete exchange of catheters over the wire. The most commonly used diameter is 0.035 inch; the distal 3 cm or so of which is ‘floppy’. Standard guidewires have a spiral design and a central stilette, and are Teflon-coated. Hydrophilic-coated guidewires are extremely slippery when wet. Although more expensive, they certainly facilitate entry into and around tortuous strictures and many endoscopists use them almost exclusively. Some wires are made with the hydrophilic coating only over the distal 70 cm or so, so that the part being handled by the assistant is not so slippery. Standard guidewires have straight (but floppy) tips. However, wires are also made with a slight preformed curve, or a tight J-tip, designed to ‘back through’ difficult areas. Smaller diameter guidewires (e.g. 0.028, 0.021 and 0.018 inch) are available for use with smaller catheters. Inevitably they kink more easily, and the tip may be somewhat more traumatic if used clumsily.

Disinfection of equipment

ERCP, more than any other endoscopic technique, carries a significant risk of introducing infection into closed spaces (i.e. obstructed ducts and pseudocysts). There have been many reported outbreaks of serious hospital-acquired infections (especially of *Pseudomonas*) traced to the use of contaminated equipment. Disinfection procedures are therefore of paramount importance. The endoscopes are disinfected in the standard manner (see Chapter 3), not only after use, but also *before* each case. Everything that can be autoclaved or gas-sterilized should be, including all catheters. Single-use accessories are increasingly popular but add significantly to the cost. We use a newly autoclaved water bottle for each case, and sterile water.

X-ray facilities

Diagnostic ERCP is a radiographic procedure initiated by an endoscopist. It is essential to have optimal X-ray equipment and rapid film processing. Some endoscopy units are fortunate enough to have their own radiology facilities. Those who have to borrow a room in the X-ray department know of the potential problems this can bring. Most endoscopists use a standard fluoroscopy or 'barium' suite, but modern digital C-arm units provide excellent screening quality and have hard-copy capabilities.

Room layout is important. There must be enough room for the endoscopist, radiologist (and/or technician) and nurse assistants (and all of their equipment). Most X-ray tables are installed close to one wall. If the patient is put on the table in the standard position for a barium examination, the endoscopist and his assistants are cramped into a corner (Fig. 6.5). Therefore, it is usually better to work with the patient's position reversed. As a result, the endoscopist and radiologist are on the same side of the table, and both can see the fluoroscopy (and video) monitor placed across from them (Fig. 6.6). When working in this position, check

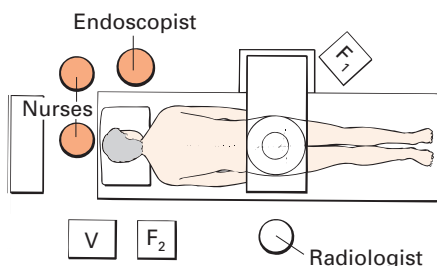


Fig. 6.5 Do not use the X-ray room in the standard 'barium' position. Nurses and the endoscopist are cramped; only the radiologist has space and can see the fluoroscopy monitor (F₁) in its usual position. The endoscopist would need an extra fluoroscopy monitor (F₂) and the radiologist cannot see the video monitor (V).

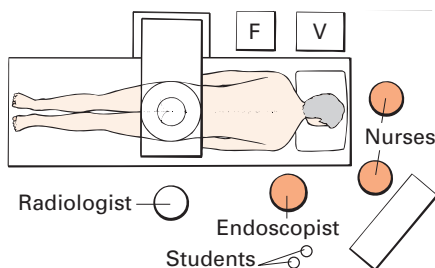


Fig. 6.6 Turn the patient so that the radiologist (or technician) and endoscopist work side by side. They, and the assisting nurse, can easily see both monitors. There is more space for the gear and students. F, fluoroscopy monitor; V, video monitor.

that the table top can travel far enough so that the patient's upper abdomen can be brought into fluoroscopic view; and also that the X-ray image can be reversed. The table should be capable of tilting at least 30° up and down.

Patient preparation

Diagnostic ERCP is performed routinely as an out-patient procedure, but post-examination observation may need to be more prolonged than after other endoscopies to detect the earliest signs of complications, such as pancreatitis.

Prior to starting the examination, the endoscopist should review the indication carefully, taking into account the latest clinical radiological and laboratory information. The aims, hazards and alternatives of the procedure are discussed fully with the patient (and relative or friend where appropriate). It is helpful to provide printed information as part of the education and consent process.

The patient should be asked about any allergy to iodine. Despite the fact that there have been no published reports of anaphylactic reactions to contrast agents during ERCP, and that there is little evidence that specific precautions are helpful, a patient's history of contrast 'allergy' should not be ignored. The procedure to be followed in this circumstance should be determined jointly by the endoscopist (or his director) in collaboration with the appropriate radiologist—and documented in the unit policy manual. Our policy in subjects believed to be iodine allergic is to use non-ionic contrast, and pre-treat with oral steroids for at least 12 h. Other details of general risk factors and precautions are given in Chapter 3.

Antibiotics should be given intravenously 1 h prior to the procedure in any patient with evidence or suspicion of duct obstruction or pseudocyst. For years we have used gentamicin with ampicillin (or vancomycin if the patient is penicillin-sensitive). Other broad spectrum regimens are acceptable.

Patients are kept 'nil by mouth' for at least 4 h before procedures, usually overnight. An intravenous line is established, preferably in the right arm (since the patient will lie partially on the left arm), and appropriate monitoring is initiated (see Chapter 3).

Procedure

The patient lies on the X-ray table with the left arm behind the back, to facilitate rotation subsequently into the prone position (Fig. 6.7). A plain radiograph is taken (in the prone position) to check exposures, to document any soft-tissue shadows (e.g. pancreatic calcification) and to ensure that the field is clear of previous contrast, monitoring wires etc.

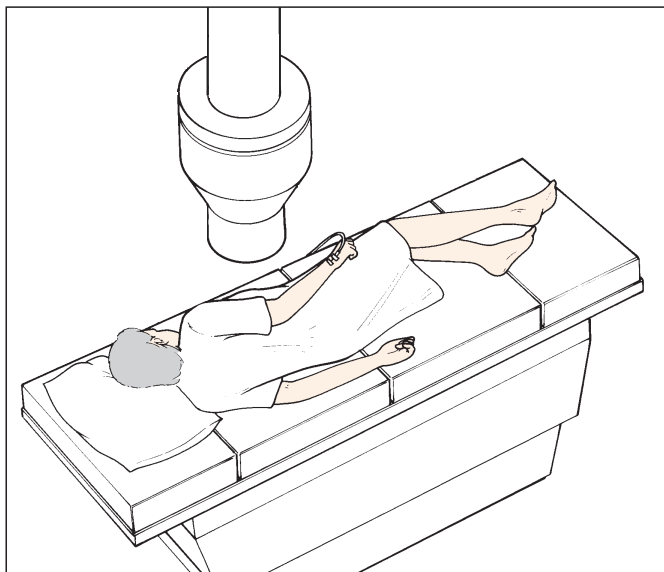


Fig. 6.7 Starting position of the patient for an ERCP.

Most patients receive standard sedation, i.e. diazepam/midazolam with pethidine (Demerol). General anaesthesia may be necessary for children and for some difficult patients and complex therapeutic procedures. Once the duodenum has been entered, it is necessary to suppress duodenal and sphincter motility. Buscopan (hyoscine *n*-butylbromide) is effective given in increments of 20 mg i.v. Glucagon is a reasonable alternative (in increments of 0.25 mg) when Buscopan is not available.

As always, check all functions of your instrument before starting.

Passing the endoscope to the papilla

Lateral-viewing instruments are easy to swallow because they have rounded tips. However, passage through the pharynx and upper oesophagus is virtually blind, so the instrument must not be pushed forcibly when there is any resistance; *gentle* pressure during swallowing should be sufficient. When intubation proves difficult, the instrument should be withdrawn and the situation reviewed. It may be wise to use a forward-viewing instrument to check for a problem (e.g. a diverticulum). Rarely, a barium study may be necessary.

Although a tunnel view is not obtained, most of the distal oesophagus can be seen with a lateral-viewing instrument if air is insufflated and the tip angled slightly down whilst pushing in or pulling out (Fig. 6.8). Excessive angulation may be hazardous and force should not be used. Slight resistance is nor-




Fig. 6.8 Examination of the oesophagus is possible with a side-viewer by angling down, but take care.

mally felt at the cardia (38–40 cm from the teeth), followed by a characteristic 'give' as the tip is advanced through it with gentle pressure.

Through the stomach and into the duodenum

- 1 Angle the tip down in the proximal stomach to view forwards; aspirate any gastric pool and insufflate air to obtain a view.
- 2 Advancing through the body of the stomach with the tip angled down provides axial views similar to those of a forward-viewing instrument (Fig. 6.9).
- 3 Rotate to obtain face-on views of all four wall of the proximal stomach when necessary (Fig. 6.10).
- 4 Pass the endoscope to the greater curvature and angle up to see the cardia (Fig. 6.11).

Passage of a lateral-viewing endoscope through the pylorus is partially a blind manoeuvre but provides no difficulty with experience.

- 1 Advance the tip through the antrum with a slight 'down' tip deflection to keep the pylorus in view (Fig. 6.12), whilst sliding the shaft inwards and around the greater curvature of the stomach.
- 2 When close to the pyloric ring, angle the tip 'up' into the neutral position (or slightly beyond it) and advance (Fig. 6.13, top). The ideal view of the pylorus during the manoeuvre is described as the 'setting sun' (Fig. 6.13, bottom).
- 3 Sometimes it may be necessary to slide over the pylorus (i.e.

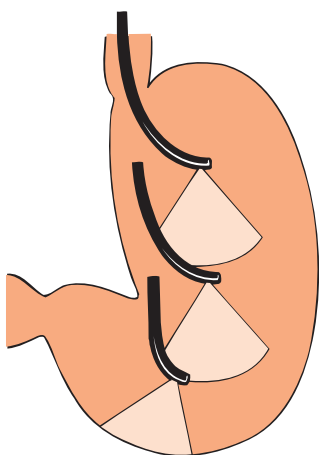


Fig. 6.9 Angle down to give a forward view before advancing the side-viewer.

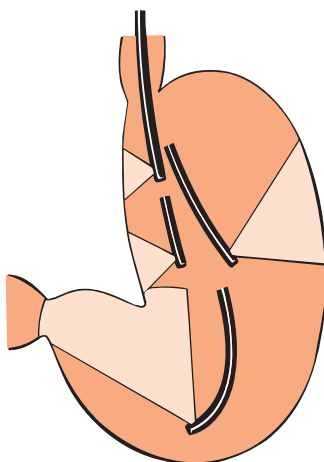


Fig. 6.10 Rotating the side-viewer gives face-on views of the whole stomach.

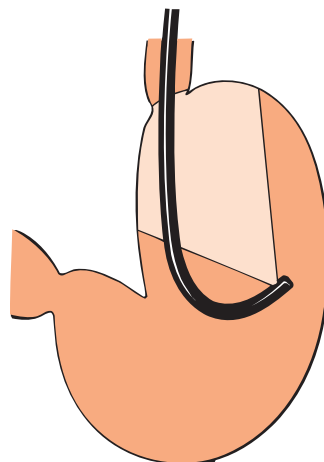


Fig. 6.11 Rotate to the greater curve and angle up to see the cardia with a side-viewer.

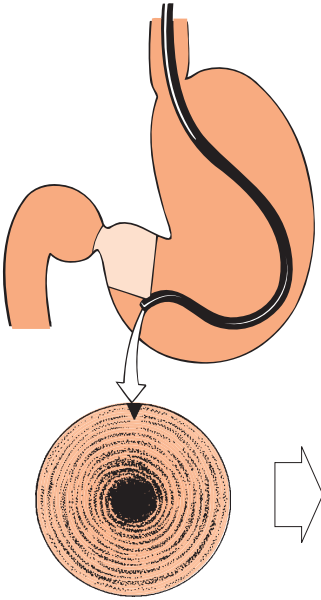


Fig. 6.12 Angle down to see the pylorus . . .

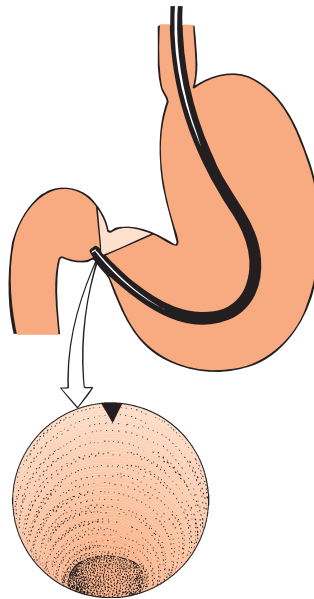


Fig. 6.13 . . . then angle up to let the tip enter the pyloric canal with a 'setting sun' view.

lose the view of it), and then angle the instrument tip sharply downwards, so as to enter the duodenum blindly.

Passage through the pyloric ring is felt rather than seen; success depends upon having the instrument in the central axis of the antrum. Check the orientation, if in difficulty, by withdrawing and angling the tip up. The angulus should be seen square-on, not obliquely, so that further upward angulation would show the instrument shaft passing down the midline of the greater curvature of the gastric body (Fig. 6.14). The lateral angling controls or shaft twist should be used to achieve the correct midline axis.

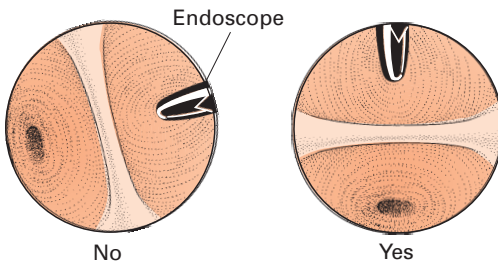


Fig. 6.14 Use twist or the lateral control to square up the angulus before passing into the pylorus . . .

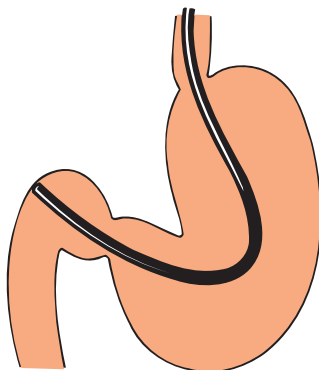


Fig. 6.15 . . . after passing the pylorus the endoscope tip tends to impact the duodenal wall.

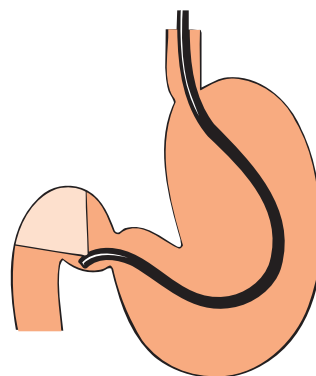


Fig. 6.16 Angle the tip down and withdraw into a hooked position to see the duodenum and cap . . .

When the instrument passes the pylorus, the springiness of the redundant loop in the stomach propels the tip inward to the distal bulb (as with forward-viewing endoscopes) (Fig. 6.15) and results in a 'red-out'. Withdraw the instrument slightly, angling the tip sharply down and insufflating some air; the tip is then virtually hooked beyond the pyloric ring, and the view is similar to that obtained with a forward-viewing endoscope (Fig. 6.16). The roof of the bulb is seen face on, and lateral tip deflection and rotation provide views of the anterior and posterior walls. The inferior part or floor of the bulb is more difficult to survey; there is a tendency to fall back into the antrum during the necessary acute clockwise rotation.

Passing the superior duodenal angle

Passing the superior duodenal angle into the descending duodenum requires a corkscrew 'right twist and pull' manoeuvre as used with forward-viewing instruments. From the bulb-viewing position the tip is angled up towards the neutral position and advanced until it is over the superior duodenal angle at the entry of the descending duodenum (Fig. 6.17). The tip is then angled acutely right and up at the same time as the instrument is rotated about 90° clockwise (Fig. 6.18). This corkscrew rotation produces a tunnel view of the upper part of the descending duodenum (Fig. 6.19) and often of the telltale bulge of the pre-papillary fold. Further tip advance can be achieved simply by pushing, but—as with forward-viewing scopes—this is *much better achieved by pulling back*, to shorten the loop in the stomach (Fig. 6.20). When the shaft has been straightened (with less than 70 cm of instrument inside the patient), the tip will lie beyond the papilla of Vater. The descending duodenum is surveyed during gradual withdrawal, using tip manipulation and rotation.

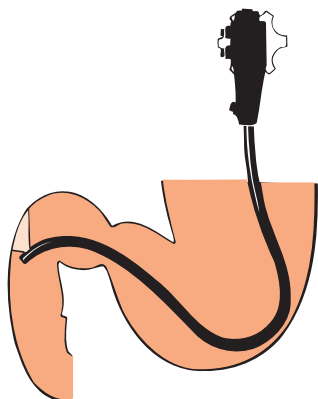


Fig. 6.17 . . . then angle up again to advance over the superior duodenal angle . . .

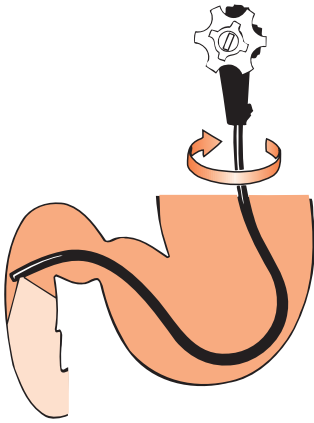


Fig. 6.18 ... and rotate 90° clockwise, whilst angling right and up, to view the descending duodenum.

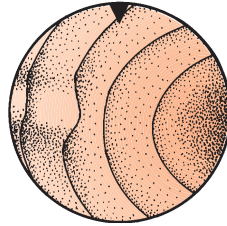


Fig. 6.19 A tunnel view of the papillary region from above.

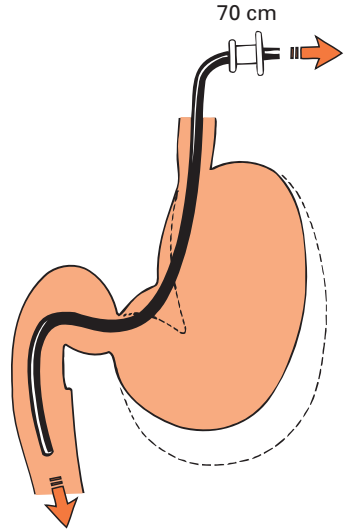


Fig. 6.20 Withdrawal helps to advance the scope into the second part of the duodenum.

Getting the instrument shaft straight is the key to cannulation success. Most beginners simply push, steer and rotate as appears visually appropriate to advance over the superior duodenal angle, and then into the second part of the duodenum. This technique is known as the ‘long route’ (Fig. 6.21). It obviates the risk of falling back into the stomach, but is unpleasant for the patient and control of the distal tip is greatly reduced. Straightening is achieved by pulling, when the tip of the duodenoscope is hooked beyond the superior duodenal angle. This manoeuvre is similar to a straightening procedure in the colon (Fig. 6.22).

The sequence of moves should become combined and automatic with practice.

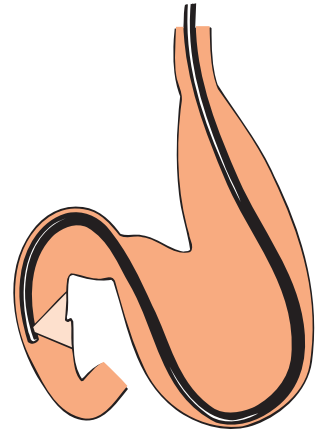


Fig. 6.21 The ‘long route’.

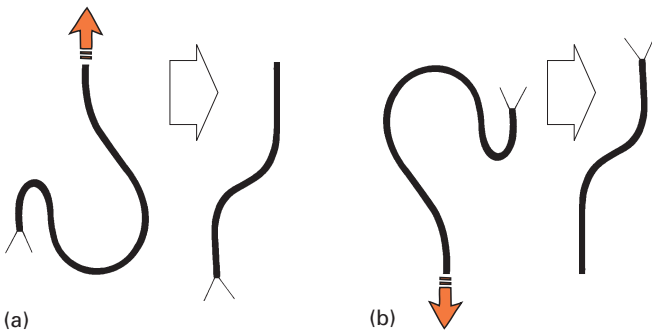


Fig. 6.22 Straightening manoeuvre in (a) the duodenum, and (b) the colon. The duodenum is the inverse of the colon.

- 1 Advance the tip to engage the superior duodenal angle.
- 2 Rotate yourself (and therefore the scope) to the *right*.
- 3 Angle the instrument tip fully to the *right* and fix it there (with the brake).
- 4 Angle the tip *up*, and withdraw the instrument slowly maintaining clockwise rotation. The instrument shaft will be straight in the 'short route' position (Fig. 6.23a) when the 60–70 cm mark is at the mouth (Fig. 6.23b).
- 5 Once the shaft is straight, the up/down and left/right control wheels can usually be released towards their neutral positions, and the patient rotated prone. The endoscopist can then turn back slightly to the left, so as to face more towards the patient. It should then be easy to find the papilla close by.

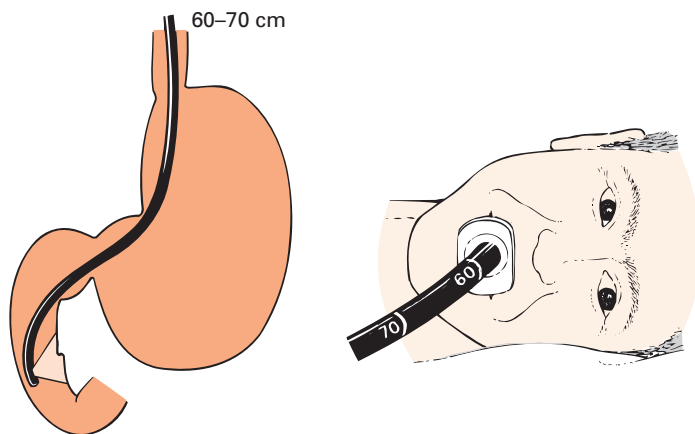


Fig. 6.23 The 'short route': (a) ... withdraw the tip and angle up to see the papilla ... (b) ... the 60–70 cm mark is at the patient's mouth.

Gastroduodenoscopy en route?

It is not difficult to examine the entire stomach and proximal duodenum with a side-viewing duodenoscope, and good views can be obtained of the distal oesophagus if the instrument tip is angled down (with care) and air insufflated. The endoscopist should decide before starting an ERCP examination whether formal gastroduodenoscopy is indicated, and must make it clear in the report whether or not it has been performed. It is remarkably easy to miss substantial lesions in the stomach and proximal duodenum when hurrying to the papilla. For the beginner, who is likely to be rather slow, there are disadvantages in attempting to be comprehensive. Prime cannulating time and conditions will be lost. However, an expert should be able to provide a complete survey and will usually wish to do so.

Finding the papilla

With the short route (Fig. 6.23), the papilla is usually in view when the straightening manoeuvre is completed. The lens automatically faces the medial wall of the descending duodenum if the patient is prone and the endoscopist is facing the patient (with the buttons facing upwards). If the papilla is not in view, the tip is usually beyond it, in the third part of the duodenum (Fig. 6.24). If in doubt, check with fluoroscopy. The shaft is withdrawn slowly (and rotated slightly from left to right) to scan the medial wall. Coming up from below the papilla, the first landmark is the angle dividing the second and third parts of the duodenum (Fig. 6.25). Above this is a bare shelf of mucosa without transverse folds. A longitudinal fold, or several oblique folds of differing size, lead over the shelf directly up to the papillary structure (Fig. 6.26).

The *normal papilla* varies considerably in size, shape and appearance. Its colour (often pinker than its surroundings) and surface characteristics (usually rough or matt compared to the shiny duodenal mucosa) make it stand out to the trained eye (Plate 6.1). It is most commonly an oval shape approximately 8 mm wide and 10–12 mm long (sometimes much smaller), tailing off below into a longitudinal fold or folds (Fig. 6.26). The course of the bile duct may be obvious as a longitudinal bulge into the lumen for 1–2 cm above the papilla. Often a horizontal 'hooding' fold crosses just above the papilla, and may sometimes hide the orifice. The orifice is at the apex of the papillary nipple. It may be patulous with several fleshy 'fronds' of protruding mucosa, or quite obscure; peripapillary diverticula are common, especially in the elderly.

Although anatomy books state that the papilla can occur in any part of the duodenal loop (and even in the stomach), it is very rarely found outside the second part of the duodenum—occasionally it is found just in the third part. If the papilla is elusive, go back to first principles with the endoscope straight. Start with the tip at the junction of the second and third parts of the duodenum (check with fluoroscopy) and then withdraw slowly again. Beginners often do not withdraw far enough, for fear of falling back into the stomach. If the endoscope does fall back into the stomach, re-passage of the pylorus may be facilitated by temporarily returning the patient to the left lateral position.

Cannulation of the papilla

Duodenal conditions must be ideal. If foaming obscures the view, infuse 20 ml of water containing a few drops of a silicone suspension down the instrument channel, and suck it back again. Further increments of Buscopan or Glucagon should be

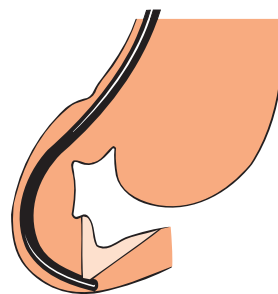


Fig. 6.24 The scope tip in the entrance of the third part of the duodenum.

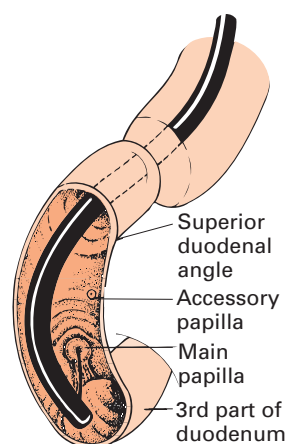


Fig. 6.25 Landmarks in the duodenal loop.

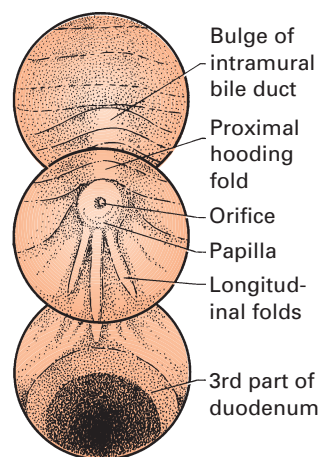


Fig. 6.26 The medial wall.

given intravenously if peristalsis is a problem. Cannulation should *not* be attempted until the papilla is seen properly face-on.

The aim is to pass the catheter through the papillary orifice in the same horizontal and vertical axes as the desired duct system — and this is the key to success. Tangential thrusts are certain to fail. Only when a reasonable face-on position has been achieved, with the patient prone and the duodenum relaxed, is the catheter passed through the instrument. To avoid injecting the air up the ducts, the catheter should be preflushed with contrast and attached to a large syringe reservoir (20–50 ml). Flushing contrast into the duodenum should be avoided because it stimulates peristalsis.

Sometimes it may be difficult to pass the catheter tip over the elevator, especially when using the long route (when the control wires are stretched). If in difficulty, straighten the instrument and insert the catheter initially with the elevator *raised*. The catheter is advanced until it abuts against the elevator; gentle forward pressure should allow the catheter tip to pass into the field of view as the elevator is gradually lowered (using the left thumb to roll the control wheel towards the operator).

It is unusual to see an actual hole in the papilla (except after surgery or stone passage), but the orifice is *always* at the apex of the nipple. Excessive fronds may make it difficult to judge the central axis of the structure. Occasionally the nipple and orifice are partly hidden by the proximal transverse fold; then the catheter tip should be used to lift the fold away (Fig. 6.27).

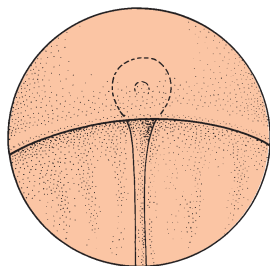
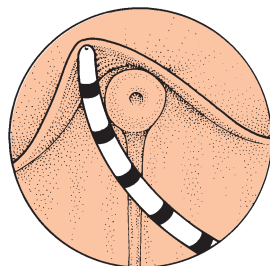


Fig. 6.27 (a) The papilla is obscured by the transverse fold ...



(b) ... use the catheter to evert the fold.

Before poking the papilla, the instrument tip should again be manoeuvred face-on, looking directly up the papillary axis. It may be helpful to use the brake to fix the left/right-angling control in a neutral position. Minor left/right adjustments are then achieved by rotating the instrument.

The cannula is placed within the orifice of the papilla, but not pressed too hard. Concentrate on trying to imagine the axis of the required duct, and swing the endoscope tip around (and advance and withdraw the instrument slightly) so as to cannulate in this axis (Fig. 6.28). Pushing the catheter may actually lose the axis due to exaggerating the curve in it (Fig. 6.29).

Contrast is injected in small increments (1–2 ml) during fluoroscopy in order to check when a duct has been entered. The endoscopist must control these injections very carefully, either by handling the syringe personally or through clear and firm ('military') instructions to an assistant. If the desired duct is visualized, more contrast is injected until optimum opacification is achieved.

Selective cannulation

The most difficult part of ERCP is learning to select the relevant duct (or ducts), and to change where necessary from one to the other. Most endoscopists find pancreatography significantly easier to achieve than cholangiography, but success should reach at least 95% for both with good technique and practice.

Selective cannulation becomes easier as manipulative co-ordination increases. ERCP is always easier the quicker it is performed, before the staff, endoscopist, patient, duodenum and papilla all become tense. Clumsily directed pokes probably induce papillary muscle spasm as well as oedema. Further small increments of Buscopan or Glucagon may help, but medication is no substitute for thoughtful gentle manipulation and, especially, remember to get the catheter into the correct axis.

Almost all patients have a single orifice for the pancreatic and biliary ductal systems, with a common channel of 1–10 mm long. Both ducts may fill simultaneously if contrast is injected when the catheter tip is only just within the orifice. However, opacification of one or both ducts may be suboptimal in this position, and contrast will also reflux back into the duodenum. *The best radiographs are obtained with deep selective cannulation.* Again, this depends on finding the correct axis, so that the catheter tip does not impact within the papilla in a fold of mucosa (Fig. 6.29). Inject only very small quantities of contrast (preferably yourself), since repeated inadvertent pancreatography increases the risk of pancreatitis. It may be possible to tell which duct has been entered without further injection if contrast is still present in the pancreas. Movements of the catheter tip will distort the distal pancreatic duct (on fluoroscopy). A catheter which passes easily for at least 5 cm is usually in the bile duct. However, this should not be assumed, since injuries can occur if contrast is forcibly injected into a side branch of the pancreas. If the catheter is deeply in the bile duct, aspiration will usually produce yellow bile (seen in the catheter under endoscopic view).

Pancreatography is more likely to result if the catheter enters the orifice perpendicular to the duodenal wall, or pointing only slightly upwards, and at approximately 1 o'clock (Figs 6.28 & 6.30). When attempting *cholangiography*, the orifice should be approached from below, and slightly from the right (aiming the catheter towards the 11 o'clock axis) (Figs 6.28 & 6.30). The idea is to enter the roof of the orifice (and common channel) when aiming for the bile duct, and to enter the floor of the orifice when seeking the pancreatic duct. Once the catheter tip has just entered the orifice, it should be lifted (or lowered) to achieve this aim (Fig. 6.31). This is more effective than approaching the papilla from too far below (Fig. 6.32). Withdrawing the scope slightly may be helpful (Fig. 6.33).

The commonest problem is changing from the pancreatic duct to the bile duct.

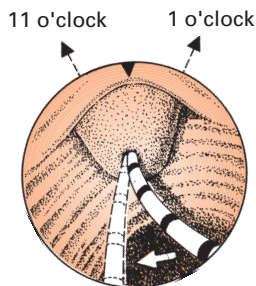


Fig. 6.28 Imagine the axis of the required duct and swing the tip around as necessary.

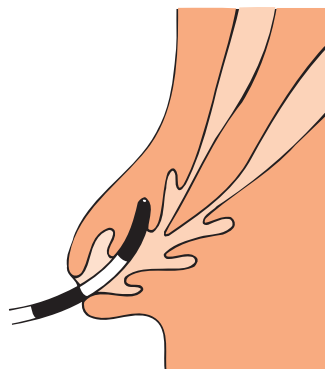


Fig. 6.29 The wrong vertical axis for deep cannulation.

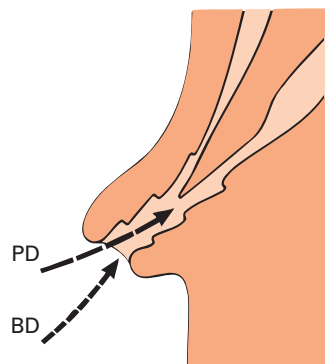


Fig. 6.30 The vertical axes for selective cannulation. BD, biliary duct; PD, pancreatic duct.

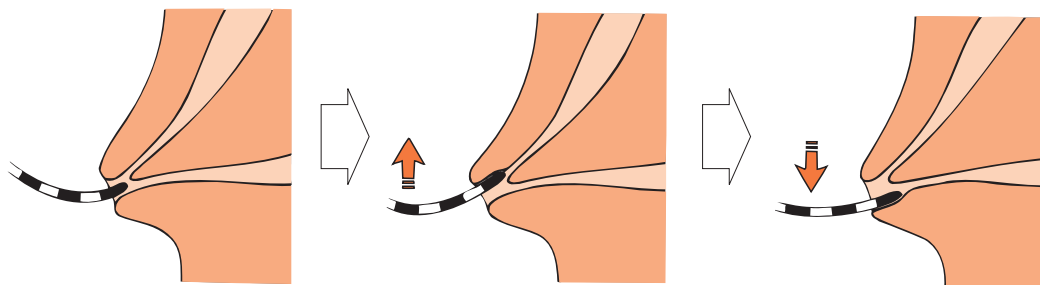


Fig. 6.31 (a) From the central catheter position . . .

(b) . . . lift up for the bile duct . . .

(c) . . . and drop down for the pancreatic duct.

The difficult bile duct

What can be done if these standard techniques are not effective? If the procedure has been prolonged and pancreatography repeated, it may be wise to desist. If the indication remains strong, the examination can be repeated at a later date or by another endoscopist. Here are the tricks we use, in the usual sequence.

- 1 *Push in and angle up.* Distorting the lateral duodenal wall may give a better view of the papilla (Fig. 6.34).
- 2 *Back off with the tip of the scope.* The natural curl of the catheter can help achieve the upward axis if the papilla is approached from a greater distance (Fig. 6.35).
- 3 Alternatively, *get very close*—the ‘kissing technique’:
 - (a) have the catheter protruding minimally and the elevator lifted fully;
 - (b) place the tip in the orifice using up angulation and scope withdrawal;

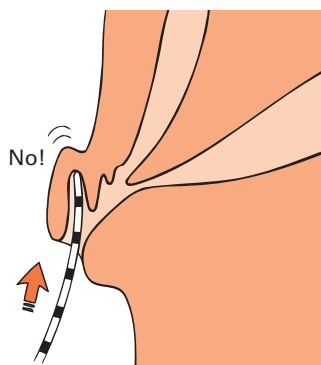


Fig. 6.32 Too much emphasis on pushing up from below is counterproductive.

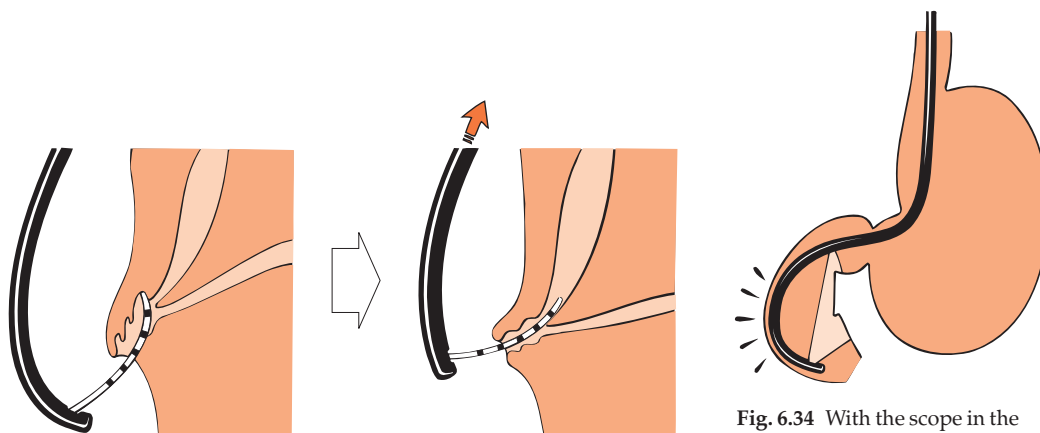


Fig. 6.33 Pull the scope back to correct the axis for bile duct cannulation.

Fig. 6.34 With the scope in the straight position, angle the tip up.

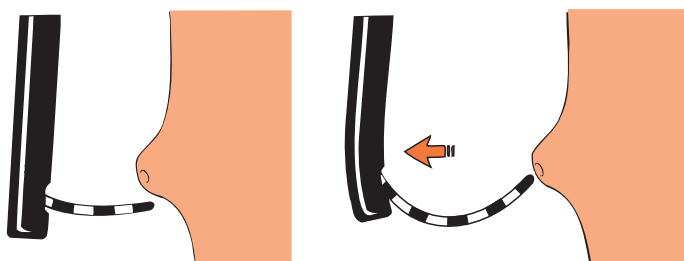


Fig. 6.35 Biliary access may be facilitated by approaching the papilla from a greater distance; the natural curl of the catheter helps orientation.

(c) rotate the scope shaft sharply to the left to lift the tip of the catheter into the 11 o'clock position in the roof of the common channel and inject contrast.

4 Use a (double-lumen) sphincterotome. This makes it possible to change the angle of approach by bowing the tip (Fig. 6.36). The stiffness of the instrument also facilitates the 'lifting' manoeuvre.

5 Try a tapered-tip catheter — carefully. Inadvertent submucosal injection can give alarming endoscopic and radiological appearances (Fig. 6.37); usually it has no adverse clinical consequences but makes completion of the procedure more difficult, at least for several days.

6 Use a guidewire (preferably hydrophilic) — carefully. Sharp wires can be traumatic, but the technique is probably safer than repeated pancreatography:

(a) the assistant holds the accessories so that the guidewire protrudes about 6 mm from the catheter tip (Fig. 6.38);

(b) probe the roof of the common channel under fluoroscopy. If the pancreatic duct still contains contrast, the guidewire can be seen *either* to enter the pancreas (the duct moves on probing) *or* to advance easily in a different direction; then it must be in the bile duct;

(c) advance the catheter into the duct over the wire, remove the wire, aspirate bile and then inject contrast.

7 Combine techniques 4 and 6 using a sphincterotome and a guidewire.

8 Pre-cutting (with a needle knife, see Chapter 7) is popular with some experts. However, there are risks involved; we recommend pre-cutting only for strong indications and not for diagnostic cholangiography alone.

The difficult pancreatic duct

When pancreatography is elusive, retrace the techniques required for obtaining the correct ductal axis.

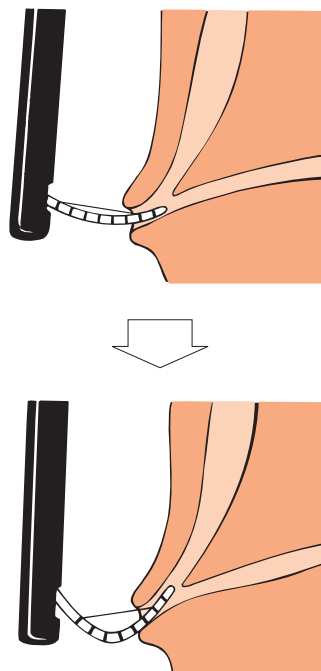


Fig. 6.36 Use the sphincterotome bowing to achieve the correct axis and push further to gain a better bile duct axis.

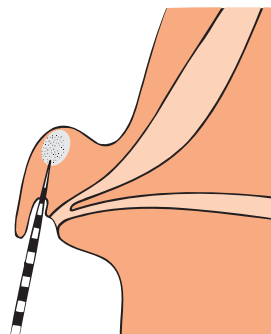


Fig. 6.37 Submucosal injection can be easily done by mistake with a sharp taper-tipped catheter.

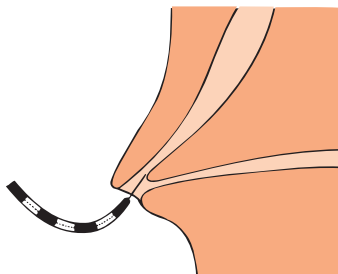


Fig. 6.38 Cannulating with a guidewire.

- 1 Place the catheter tip in the lower margin of the orifice, press it downwards by lowering the elevator and aim slightly more to the right (1–3 o'clock position).
- 2 Try the same technique with a tapered catheter.
- 3 Use a hydrophilic guidewire.

'Failure' may be due to the congenital anomaly of the pancreas divisum, where the main (or only) drainage is via Santorini's duct and the minor papilla. Sometimes a very small ventral pancreas can be identified only if radiographs are taken during contrast injection (Fig. 6.39) even when nothing can be seen on fluoroscopy.

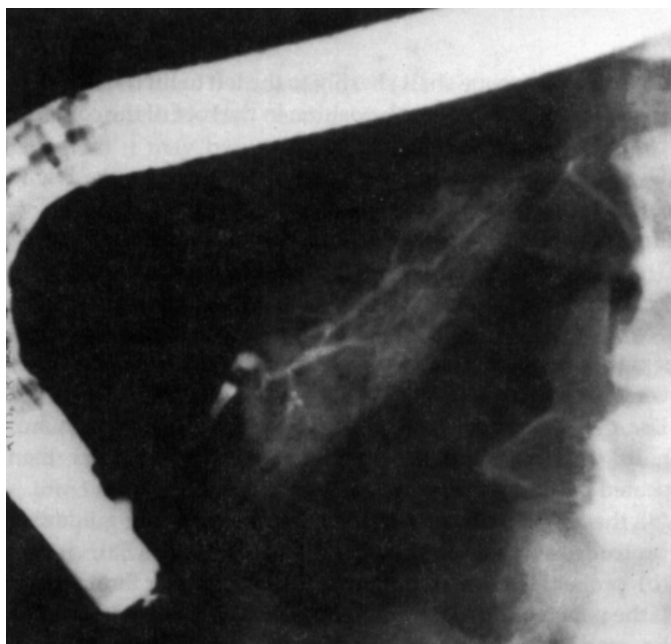


Fig. 6.39 Endoscopic pancreatogram showing a small ventral pancreas.

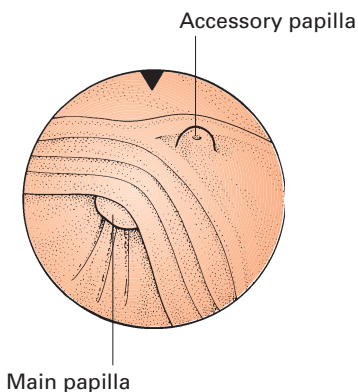


Fig. 6.40 Position of the accessory and main papillae.

Cannulation of the accessory (minor) papilla

This should be attempted when contrast injection through the main papilla does not provide the required pancreatogram, and when it shows only a separate ventral pancreas. The minor papilla can be identified in virtually all patients, approximately 2 cm above and slightly to the right of the main papilla (as seen at endoscopy), lying just below the superior duodenal angle (Plate 6.1). Its size varies considerably, from a tiny blind nodule to a major structure which can be mistaken for the main papilla. Unlike the main papilla, it does not have any distinct longitudi-

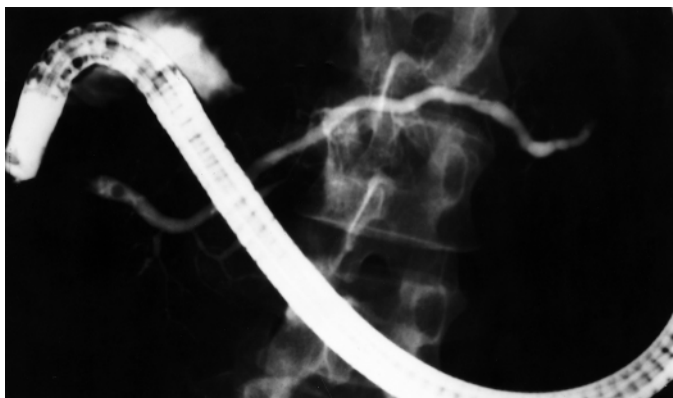


Fig. 6.41 The endoscope in the 'semi-long' position often provides the best face-on access to the minor papilla.

nal structure, being solely a hemispherical nipple found characteristically at the junction of two transverse folds (Fig. 6.40). A face-on position for cannulation of the minor papilla is best achieved using a 'semi-long route' (Fig. 6.41).

- 1 Bring the endoscope back into the duodenal bulb with the shaft straight.
- 2 Push it again whilst angling to the *left* to wedge the tip and prevent it advancing over the superior duodenal angle.
- 3 When the shaft is 'half-long', slight right rotation of the instrument and right angulation will corkscrew the tip over the superior duodenal angle, and will usually reveal the minor papilla.

The papilla can be made more prominent and the orifice visible if the pancreas is stimulated with secretin (give 25–50 units i.v. and wait 3 min). A problem with using secretin is that contrast must then be injected against a flow of juice. Whilst this does not appear to be dangerous, it may prove difficult to outline the entire duct system without using excessive pressure.

Minor papilla cannulation is best attempted with fine-tipped catheters; we prefer a short metal tip. Alternatively we use a 0.018-inch guidewire protruding from a taper-tipped catheter, after secretin injection. Once the guidewire is inserted, the catheter tip is slid into the orifice. The guidewire is removed and contrast is injected. However, there will be air in the catheter after removal of the guidewire, so the pancreatogram may be incomplete.

Dorsal duct cannulation should succeed in over 80% of cases. However, pancreas divisum (or dominant Santorini drainage, whether congenital or acquired) can be diagnosed without opacification of the dorsal duct by giving secretin; clear juice flows from the minor papilla, occasionally like a fountain.

Radiographic technique

The slickest cannulation is of no avail (and may be a disservice to the patient) without good radiological technique. It is not necessary to have a radiologist present throughout all the procedures, but some collaboration with radiology staff is essential. A specially trained radiology technician can help achieve the goal of providing high-quality studies and can ensure the maintenance of X-ray safety standards. Physical layout and the issues of contrast allergy have already been discussed. Standard water-soluble contrast agents are used, as for urography (e.g. Renografin, Urografin, Conray, Angiografin). This is no evidence, as yet, that non-ionic contrast agents are safer. We start with full strength (in a 20 or 50 ml syringe attached to a pre-flushed catheter), but change to a less dense mixture (15–25%) when filling dilated ducts. This reduces the risk of missing small stones (or even quite large stones in a very dilated system), and makes it easier to see catheters and guidewires on fluoroscopy. The optimum amount of contrast is judged solely by fluoroscopy and intermittent radiographs; injection continues until the relevant ducts are fully outlined without overdistension. The total volume of contrast is irrelevant; this depends upon which system is being filled and how much is spilled into the duodenum.

Pancreatography

Radiographs always show more detail than fluoroscopy (depending on the equipment). By the time the pancreatic duct tail can be seen on fluoroscopy, radiographs usually show filling of all major branches. Opacification of the parenchyma (acinarization) should be avoided. The appearance of a urogram during ERCP is a sign that a large volume of contrast has been injected (and absorbed); there is then an increased risk of pancreatitis.

Contrast leaves the normal pancreatic duct system rapidly and is often completely cleared within 5 min. Radiographs should therefore be taken during contrast injection with the instrument and catheter in place. The prone position is convenient, and a 'straight scope' does not usually overlie the pancreas (as would a long scope) (Figs 6.42 & 6.43). Oblique films may be necessary to clarify local duct changes and to separate areas of interest from the vertebral column. Lateral views are rarely necessary and are often confusing.

Cholangiography

Many cholangiograms produced by beginners are inadequate for interpretation. The whole biliary tree (and gallbladder when present) must be filled, and views taken in appropriate posi-

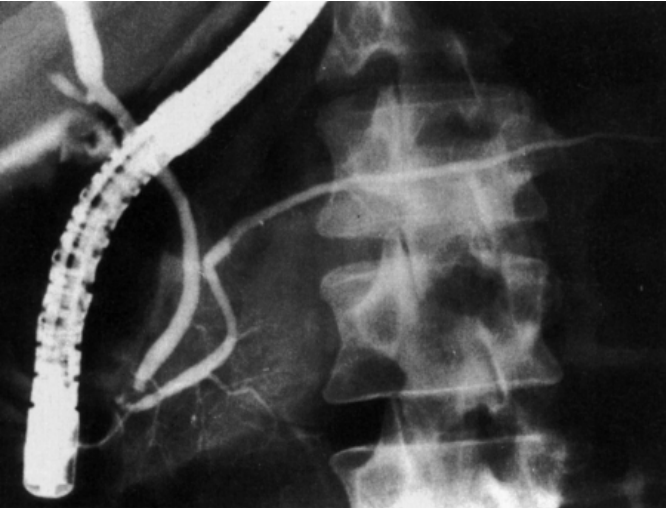


Fig. 6.42 A normal pancreatogram (and part cholangiogram) with the instrument in the 'short scope' position.

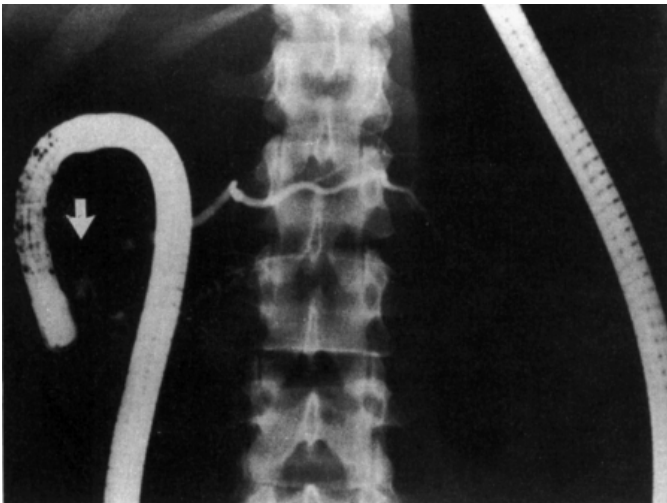


Fig. 6.43 Instrument with a long loop in the stomach (the 'long route'). The papilla of Vater is arrowed.

tions. In the prone position the right intrahepatic ducts fill last (because they are 'uphill') (Fig. 6.44), and the gallbladder fundus may not be seen.

After cholecystectomy the biliary tree may be completely 'full' with bile in the resting state. Contrast injection may result in pain though overdistension, even before adequate opacification is achieved. Thus, it is good practice to aspirate bile once deep biliary cannulation has been achieved. We try to exchange

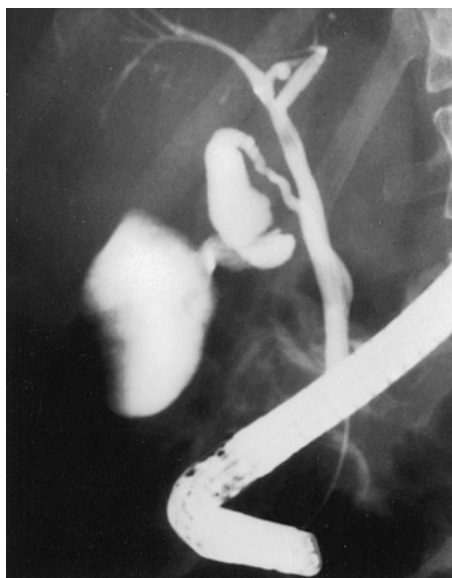

Fig. 6.44 Retrograde cholangiography showing poor filling of the right intrahepatic ducts during injection in the prone position.

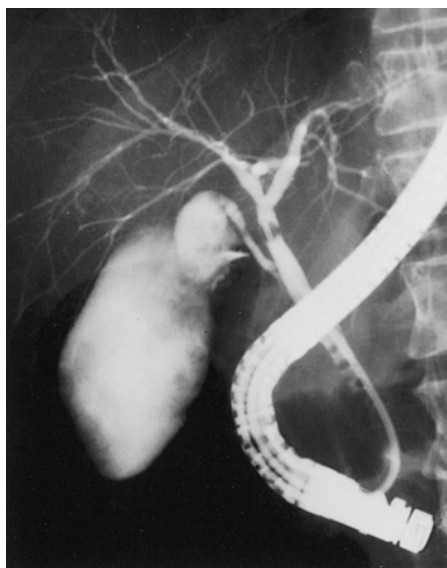
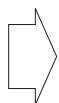

Fig. 6.45 Further injection after occluding the common hepatic duct with a balloon gives better intrahepatic filling.

contrast for bile, volume for volume. This is particularly important in the presence of infected bile, since increasing the biliary pressure can provoke bacteraemia. When the gallbladder is present, it acts as a reservoir and may (because it fills preferentially) prevent adequate views of the upper biliary tree. To provide good intrahepatic cholangiograms it is usually necessary to inject when the tip of the catheter is above the cystic duct orifice. Even better and selective filling of the biliary tree can be achieved by the *balloon occlusion technique*. A balloon-tipped catheter (as used for stone retrieval) is placed in the common hepatic duct, if necessary with the use of a guidewire. Contrast is injected after the balloon is inflated (Fig. 6.45).

To obtain good views of the whole biliary tree it may also sometimes be necessary to rotate the patient (usually to the right), tilt the table and temporarily push the endoscope in deeper to form a loop in the stomach, so as to expose the mid-duct which is otherwise overlain by the catheter (Fig. 6.46). We also usually take radiographs after the scope has been removed, with the patient supine and rotated slightly to the right (to separate the bile duct from the vertebral column). These and other views are necessary to provide a full perspective of the gallbladder (when present), facilitate study of the sphincter zone in contraction and relaxation (Fig. 6.47) and to help differentiate stones from air bubbles.

Delayed films may sometimes be helpful. When gallbladder

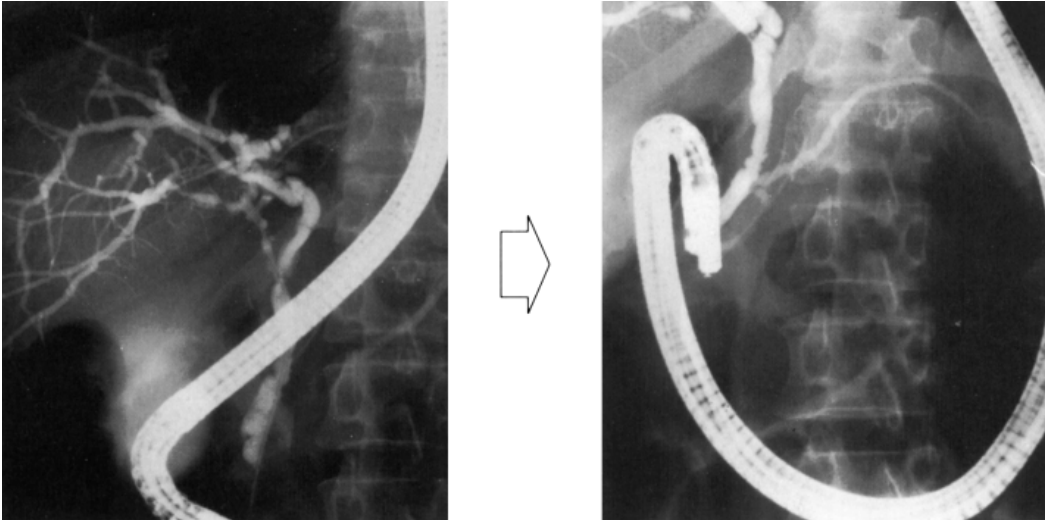


Fig. 6.46 Changing the position of the endoscope may provide better views of the common bile duct.

disease is suspected, delayed radiographs should be taken at 1–2 h, at which time the patient can be moved around more easily and contrast mixing is more complete. Small gallstones can be detected in the fully erect position and compression views may also be helpful. Abnormalities of gallbladder emptying can be detected by serial films taken at 30 and 60 min after i.v. injection of cholecystokinin (25–50 units) (Fig. 6.48). Some experts routinely take *drainage films* if sphincter dysfunction is suspected in a patient who has previously undergone cholecystectomy. Lack of complete duct drainage after 45 min is often considered

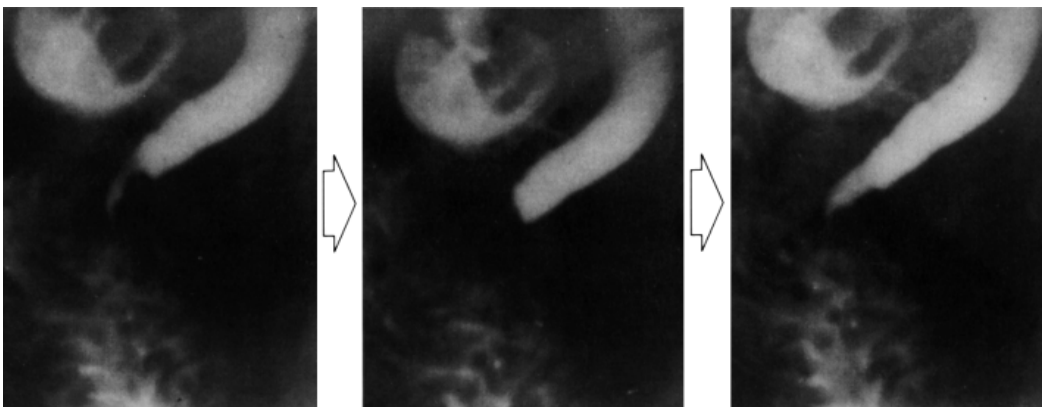


Fig. 6.47 Sequential views of the bile duct termination during relaxation and contraction.

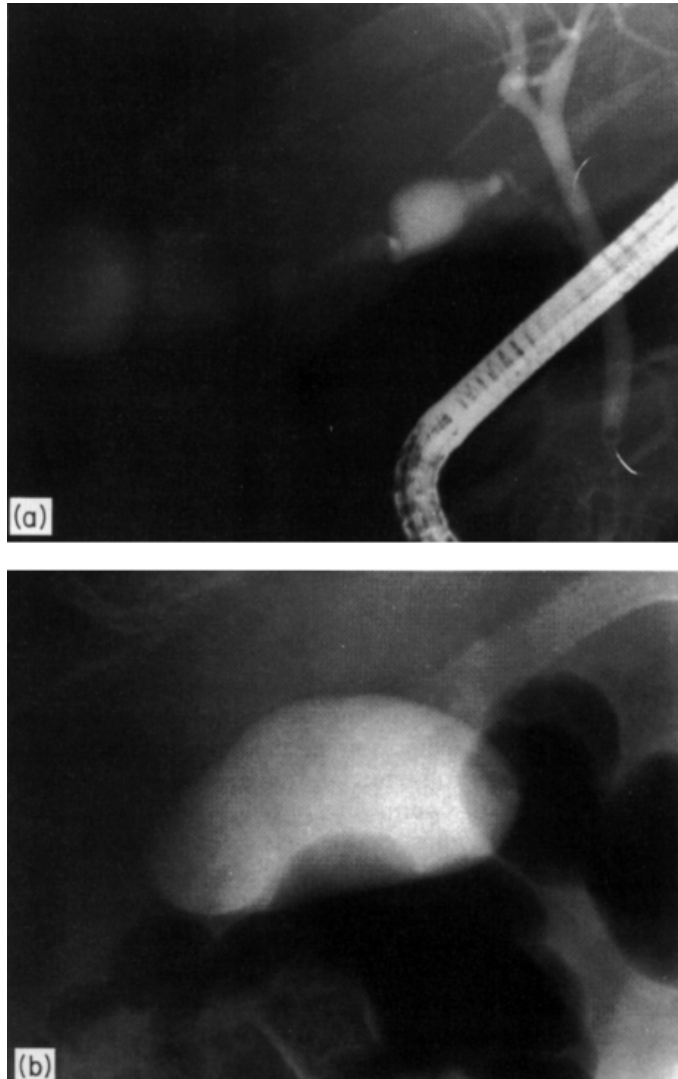


Fig. 6.48 (a) Initial filling of the gallbladder (with contrast streaming) at retrograde cholangiography. (b) Inadequate emptying and asymmetrical shape of the gallbladder after injection with cholecystikinin.

abnormal. However, control data are scarce and the drainage must be influenced by the medication employed as well as the trauma of a difficult cannulation.

ERCP in children

Experimental small paediatric instruments are available, but the standard duodenoscope can be used (with the straight scope

technique) down to the age of about 1 year. Success in neonates has been reported. Small-diameter, more flexible taper-tipped catheters preformed with a tight distal curve are easier to manoeuvre in the close confines of the infant duodenum. Actual cannulation is usually easy, often with simultaneous filling of both duct systems. We use general anaesthesia up to the mid-teens, since it is essential for the patient to remain still. General anaesthesia eliminates normal warnings of discomfort, and care must be taken to avoid unnatural manipulations and the excessive use of air and contrast.

Cannulation problems

Problems due to local disease

Diverticula. Diverticula close to and surrounding the main papilla are the commonest pathological reasons for cannulation difficulty. They occur frequently, especially in elderly patients with duct stones. Small diverticula are shallow caves, most frequently seen above the papilla at the 9–11 or 1–3 o'clock positions, when seen face-on (Fig. 6.49). Larger diverticula may override the papillary mass and eventually 'swallow' it, so that the orifice actually lies within the diverticulum. The papilla can sometimes be persuaded out of the diverticulum by probing the folds radiating towards it with the cannula, and then using a combination of endoscope tip manipulation and duodenal deflation. Once the orifice is visible, it is often helpful to 'hook' the papilla out of the diverticulum using the tip of a sphincterotome (with or without a guidewire). Occasionally it is necessary to place the tip of the duodenoscope actually within the diverticulum, but this must be done very carefully. Diverticula are sometimes also seen around the accessory papilla.

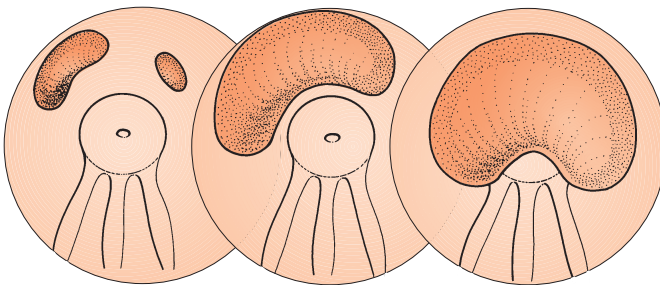


Fig. 6.49 Diverticula around the papilla.

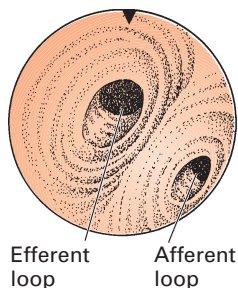


Fig. 6.50 Usual orientation in Billroth II gastrectomies and gastroenterostomies.

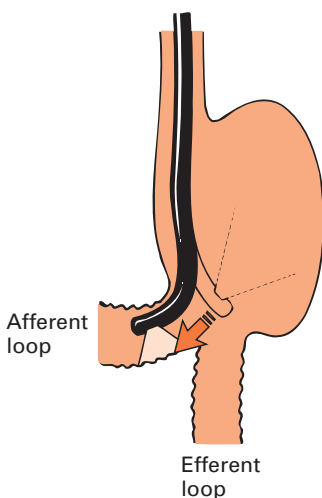


Fig. 6.51 'Backing in' to the afferent loop.

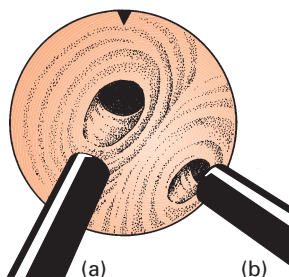


Fig. 6.52 (a) Usual approach. (b) Approach for access to the afferent loop.

Malignancy. Malignancy of the papilla or periampullary region can also cause difficulty (Plates 6.2 and 6.3). Pancreatic tumours may simply distort the anatomy or ulcerate through the floor of the bulb or the medial wall of the descending duodenum. The endoscopic appearance of an ulcerating malignancy is fairly characteristic, and biopsy specimens should confirm the diagnosis. When the tumour remains submucosal, the endoscopic appearances of oedema and irregularity are similar to those seen in patients with active pancreatitis. A large mass lesion in the pancreas (tumour or pseudocyst) often makes it more difficult to straighten the endoscope.

Most primary tumours of the papilla are obvious endoscopically, and the diagnosis is easily confirmed by biopsy and/or brush cytology. The orifice is usually in the centre of the tumour mass. Look carefully for clues (especially for any trace of bile) before touching the papilla, which often bleeds easily.

Deformity. Deformity of the papilla can occur for other reasons. The apex of the papilla may appear lumpy, oedematous and congested in the absence of tumour or previous surgery. Impacted stones cause a prominent oedematous papilla, and the orifice may be obscured below it (Plate 6.4). Cannulation is often most easily achieved with a sphincterotome, used to 'hook' it upwards. Impacted stones may cause a fistula at the apex of the oedematous papilla (above the normal orifice), as may surgically and percutaneously placed catheters (Plate 6.5). The orifice may be lax and ragged soon after the passage of a stone.

Problems due to previous local surgery

Billroth II gastrectomy. This is the commonest anatomical problem for ERCP. The orifice of the afferent loop is usually less obvious than that for the efferent loop, and more difficult to enter. The correct orifice is usually (but not always) found in the 2–5 o'clock sector when viewing the stoma (Fig. 6.50). Entry to this loop can often be achieved by 'backing in' (Fig. 6.51), a similar technique to that used to enter the ileum at colonoscopy. The tip of the endoscope is placed over the orifice and angled sharply downwards. It may also be helpful to approach the stoma from about 3 o'clock, rather than the usual 6 o'clock position (Fig. 6.52).

Once in a loop, there are no useful landmarks until the papilla is recognized. To see increasing amounts of bile (or resulting bubbles) whilst advancing is encouraging. Fluoroscopy is somewhat helpful, but only in the negative sense of being sure the scope is in the 'wrong' (efferent) loop when fluoroscopy shows the endoscope tip to be deep within the pelvis. When confident of being in the *wrong* loop, it may be helpful to take a few biopsies just below the stoma, to leave a little blood as a marker of the

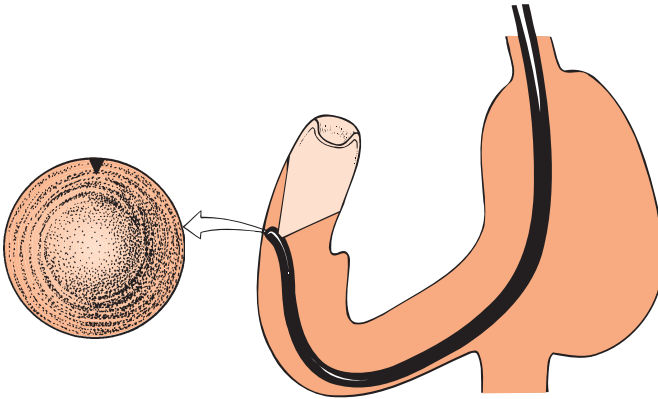


Fig. 6.53 An invaginated duodenal stump may resemble a polyp.

wrong route. Once in the afferent loop, it may be possible to recognize the telltale bare shelf (or longitudinal fold) below the papilla in the distal half of the second part of the duodenum. The other landmark is the blind termination of the duodenal loop, which (because invaginated) may resemble a smooth polyp (Fig. 6.53).

Be careful as excessive stretching of the loops can result in perforation, especially in elderly patients.

Cannulation in Billroth II patients is more difficult because everything is upside down (Plate 6.6); the natural curl of standard catheters is counterproductive (Fig. 6.54). For the same reason, cholangiography is much more difficult to achieve than pancreatography. Several techniques are helpful in trying to overcome this problem of orientation.

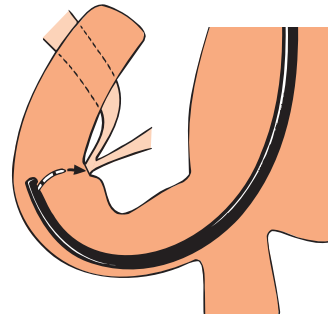


Fig. 6.54 The natural curl of the catheter is unhelpful.

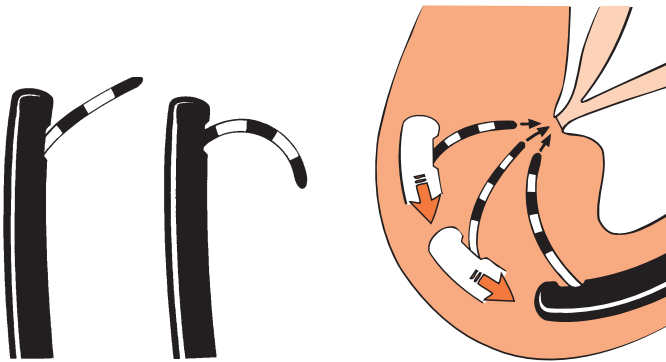


Fig. 6.55 A new catheter tends to curl less than an old one.

Fig. 6.56 Withdrawing the scope produces a better catheter axis but a more distant approach.

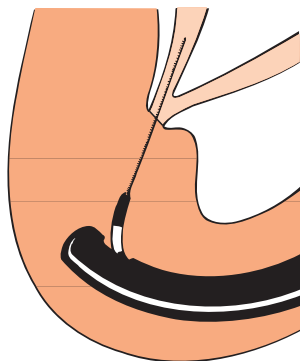
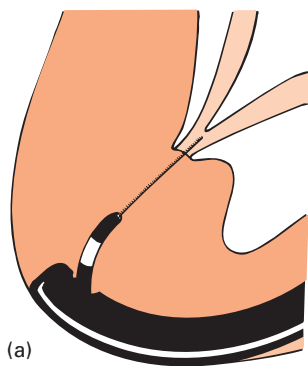
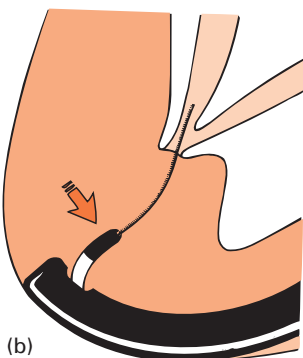
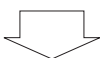


Fig. 6.57 Cannulating with a guidewire.



(a)



(b)

Fig. 6.58 (a) Having placed the tip of the guidewire in the orifice, (b) its direction can be changed by altering the catheter direction with the elevator.

A new catheter tends to go straighter than an old one (Fig. 6.55). Pulling the scope back to the junction of the second and third parts of the duodenum can change the angle of attack appropriately, but it may then be necessary to attempt cannulation from a distance (Fig. 6.56). Our favoured method involves the use of a 0.035-inch guidewire, protruding from the tip of a standard catheter or inner 'guiding' catheter of a stent set. The guidewire travels in a straight line (until it reaches the papilla). Its angle of approach can be altered by changing the length of guidewire protruding from the catheter, as well as by use of the elevator (Fig. 6.57). Once the tip of the guidewire has been impacted in the orifice of the papilla, its direction can be altered somewhat by looping manoeuvres (Fig. 6.58).

Some experts favour an end-viewing instrument for Billroth II cannulation. In theory, the lens looks directly into the axis of the papilla (Fig. 6.59). However, the lack of an elevator often makes detailed cannula movements more difficult, and we prefer the standard side-viewing duodenoscope. A long floppy (paediatric) colonoscope may be helpful in patients with a very long afferent limb, or when attempting cannulation up a rouxen-Y loop. Cannulation in the latter situation is almost impossible without a combined percutaneous-endoscopic approach (see Chapter 7).

Billroth I gastrectomy, pyloroplasty and gastroenterostomy. These should not interfere with ERCP (provided the pylorus is patent).

Surgery of the papillary region. Surgery of the papillary region may produce confusing appearances. Duodenotomy results in a puckered scar on the lateral wall of the duodenum, which may slightly reduce its lumen and affect endoscopic manoeuvrabil-

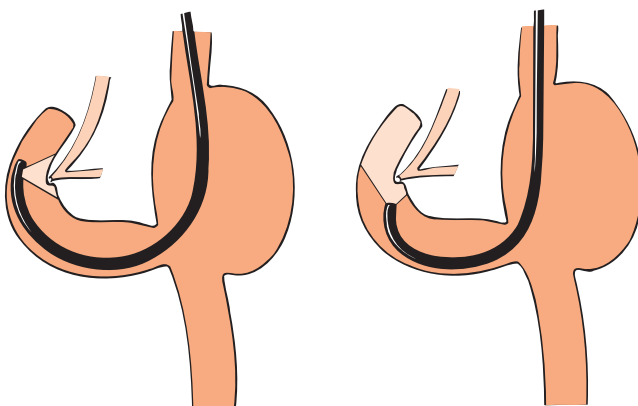


Fig. 6.59 Some experts prefer a forward-viewing scope to obtain better alignment at the papilla, especially for the bile duct.

ity; these scars can be misdiagnosed as polyps and tumours by the unwary. Papillary appearances after surgical sphincterotomy vary from normal to a wide-open biliary orifice. Standard surgical sphincteroplasty results in a gaping hole, dribbling bile and blowing bubbles; the pancreatic duct orifice is usually visible in the floor of the sphincteroplasty (Fig. 6.60).

Choledochoduodenostomy stoma. This is usually easy to find in the roof or left lateral wall of the duodenal bulb, but can escape detection when stenosed. Cannulation of a tight stoma may require a guidewire. When the orifice is widely patent, a balloon occlusion catheter technique will provide good radiographs. It may be necessary to use a guidewire to facilitate selective cannulation of the upper and lower limbs.

Operations on the pancreas. These do not usually involve the papillary region and cannulation is unaffected. The standard Whipple procedure usually takes the biliary and pancreatic duct orifices out of endoscopic reach. The site of a pseudocystogastrostomy looks like a ragged pale gastric ulcer (which usually heals completely within a few weeks).

Specimen collection

Pure bile and pancreatic juice. These can be collected by aspiration after deep cannulation of the relevant duct. Very little pancreatic juice is obtained without an intravenous injection of secretin. Bile can be inspected for microcrystals, and pancreatic juice analysed for bicarbonate. More complex analyses are experimental. The results of juice cytology (both pancreatic and biliary) have been disappointing; yields are higher with direct intraductal brushing.

Brush cytology specimens. These can be taken from deep within the ductal systems using a dual-channel sleeve passed over a guidewire (Figs 6.61 and 6.62).

Biopsies. Biopsies can be taken in the standard manner from lesions of the papilla and surrounding structures. Large specimens can be taken from proliferative tumours using diathermy snare loops (Plates 6.2 and 6.3). Some tumours confined within the papilla are detected only after a sphincterotomy has been performed for apparently benign papillary stenosis.

Biopsy samples can be taken from within the biliary and pancreatic ducts under fluoroscopic guidance with standard or smaller forceps. These can be passed through the normal papilla, but are easier to manipulate after a sphincterotomy or through a preplaced covering sleeve. Biopsies can also be taken under

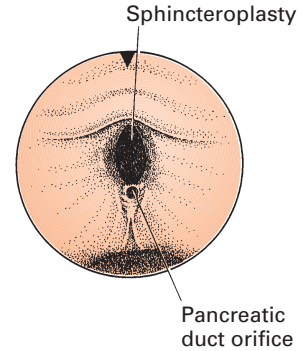


Fig. 6.60 Standard sphincteroplasty.

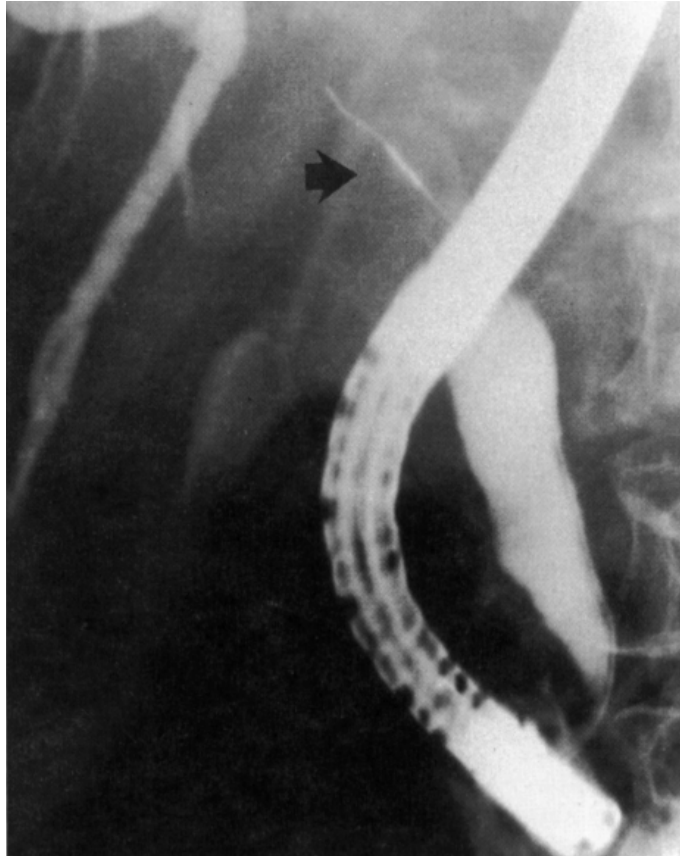


Fig. 6.61 A cytology brush (arrowed) passed deep into the common hepatic duct.




Fig. 6.62 Double-lumen brush cytology device.

direct vision from within the duct systems, using a 'mother and baby' choledochoscope (Fig. 6.63; Plate 6.7).

Needle-aspiration specimens. These can also be obtained from within the ductal systems, or even directly through the wall of the duodenum into a submucosal mass.

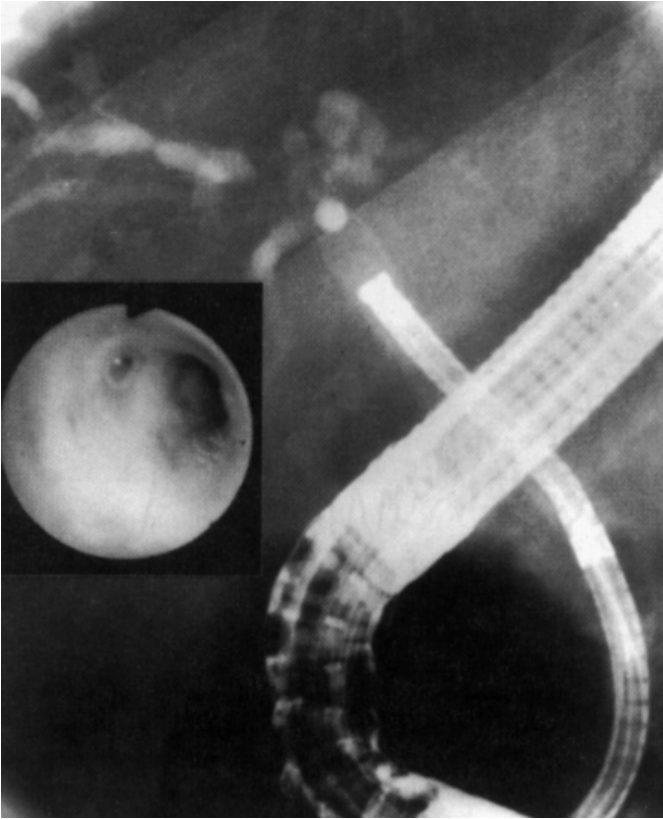


Fig. 6.63 Radiography showing the 'baby' choledochoscope passed up the bile duct through the 'mother' instrument.

Sphincter of Oddi manometry

Dysfunction of the sphincter of Oddi can cause biliary pain (especially in the post-cholecystectomy situation) as well as recurrent pancreatitis. ERCP has brought the problem of 'papillary stenosis' into closer focus by making it easier to rule out other causes, such as stones or tumours. Pressures can be measured in the ducts and sphincter zones by standard manometric techniques, using a triple-lumen perfused catheter system at the time of ERCP (Fig. 6.64). Endoscopic manometry is often difficult for the endoscopist and the patient since medication must be minimized. Interpretation of the tracings is often subjective (Fig. 6.65). Furthermore, manometry appears to increase the risk of pancreatitis above that expected for standard ERCP. For these reasons, sphincter of Oddi manometry is restricted to a few special centres, and attempts are being made to obtain similar diagnostic information by less invasive methods.

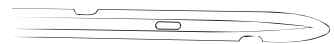

Fig. 6.64 Triple-lumen catheter tip for manometry.

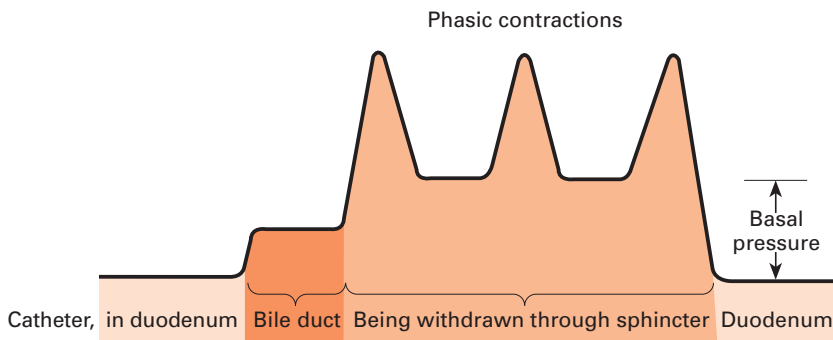


Fig. 6.65 (a) Stylized manometry trace.



(b) Actual tracing from a patient showing potential difficulties in interpretation.

Radiographic interpretation and artefacts

Cholangiograms are relatively familiar, and retrograde studies resemble those obtained by other techniques. Specific artefacts caused by layering and streaming of contrast, and also by the introduction of air bubbles, can be recognized and eliminated by good technique. There should be relatively few problems of interpretation. Bile duct size remains a controversial issue (especially after cholecystectomy). There is little evidence that the bile duct increases in size after cholecystectomy (in the absence of pathology); thus a 'dilated' duct cannot be interpreted as indicating obstruction unless it is known that the bile duct was smaller at the time of surgery. The appearance of the terminal bile duct is very variable, and overinterpretation is more common than the reverse. Numerous views taken during emptying may resolve diagnostic problems (see Fig. 6.47). It can be difficult to decide whether a distal biliary stricture is due to pancreatitis or carcinoma, but coincident pancreatography may help. Radiographic distinction between sclerosing cholangitis and cholangiocarcinoma may be impossible, and the diagnostic specificity of changes in the intrahepatic biliary tree remains controversial. Beginners are often surprised by the low insertion of the cystic duct, but this is very common. Failure to opacify the gallbladder indicates pathology only if sufficient contrast has entered the biliary system to demonstrate the entire intrahepatic tree.

Pancreatograms are less familiar than cholangiograms, and are often more difficult to interpret than to obtain. The course of

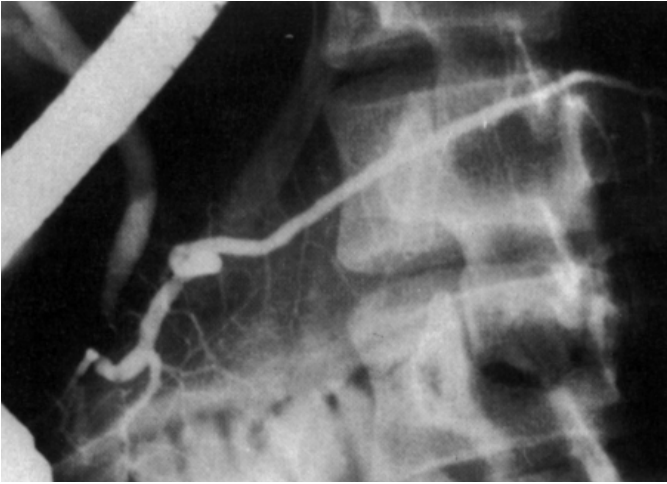


Fig. 6.66 Good-quality normal pancreatogram.

the main duct varies considerably. It usually ascends almost vertically in the head; after a sharp turn or loop at the neck it crosses the vertebral column horizontally or slightly upwards towards the tail. No diagnostic significance can be attributed to odd shapes of the pancreatic duct. The mean diameters of the main duct in the head, body and tail of the normal pancreas are approximately 4, 3 and 2 mm, respectively, but the upper limits of normality are closer to 6, 4 and 3 mm. These figures are corrected for the radiographic magnification (usually about 30%) by checking the apparent endoscopic diameter on the radiographs. There is some increase in pancreatic duct diameter beyond middle age. First and second order branches are usually visible throughout the gland (with good technique), but the distribution and course of these branches is variable (Fig. 6.66). There are fewer branches over the vertebral column where the pancreas is thinner.

Congenital variations in the duct relationships in the head of the pancreas are predictable from their embryological derivation. There is often a narrowing in the main duct close to the junction with Santorini's duct — an appearance which should not be misinterpreted as pathological. The absence of upstream dilatation should provide reassurance. Complete non-union of the ventral and dorsal segments gives rise to pancreas divisum (Fig. 6.67). Cannulation of the main papilla then shows only the ventral pancreas (see Fig. 6.39). This may be very small or even absent. The dorsal duct becomes dominant and drains the bulk of the pancreas through Santorini's duct and the accessory papilla (Fig. 6.68). Santorini's duct may be dominant even when union occurs—the partial pancreas divisum (Fig. 6.69).

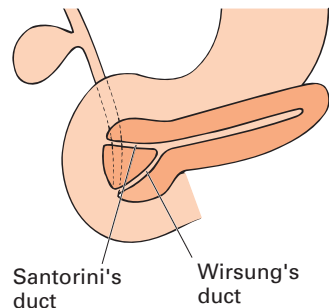
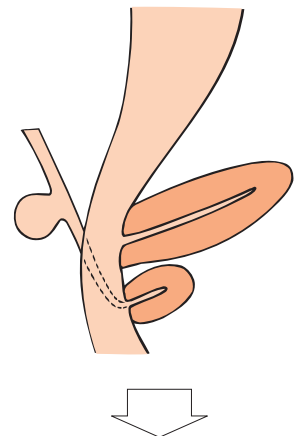
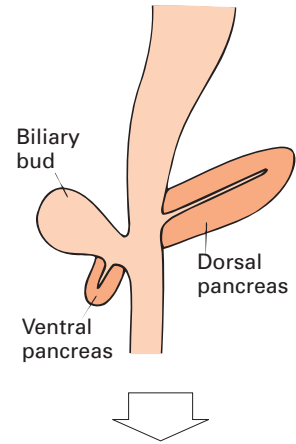


Fig. 6.67 Embryonic development of the pancreas. Arrest at mid-phase results in pancreas divisum.

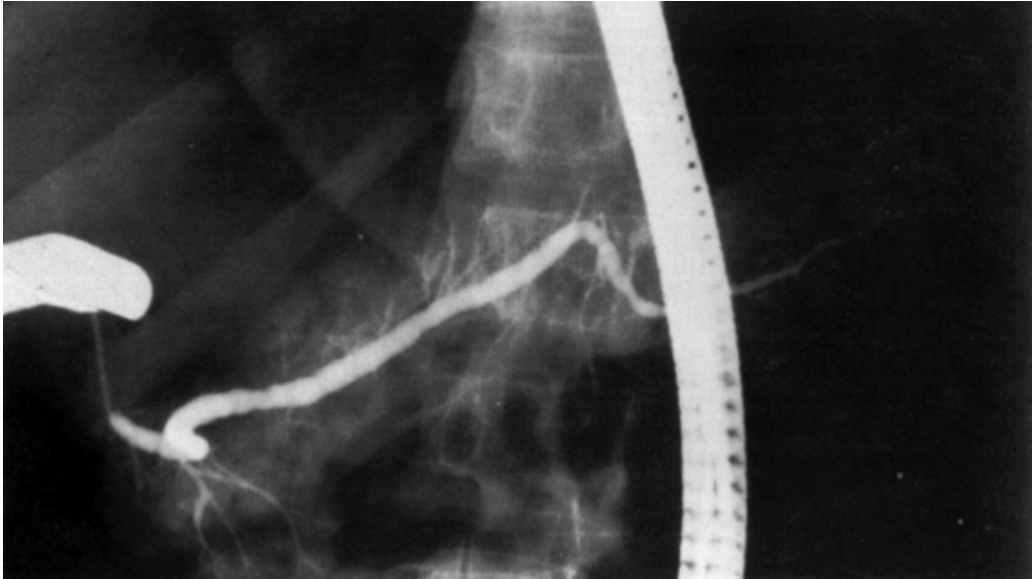


Fig. 6.68 Normal dorsal pancreatogram achieved by cannulating the accessory papilla and filling the body and tail of the pancreas through Santorini's duct.

Pancreatograms are usually grossly abnormal in patients with ductal adenocarcinoma, showing complete obstruction or a tight stricture with upstream dilatation. Tumours which do not arise in the ductal system are less apparent, and tumours of

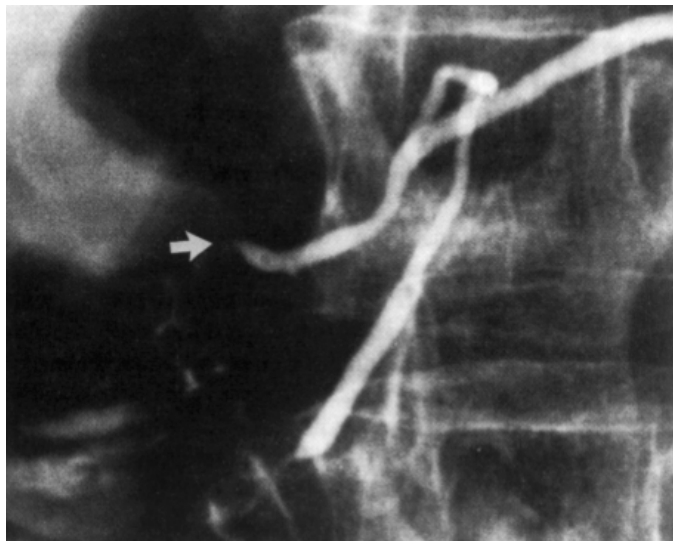


Fig. 6.69 A dominant Santorini duct discharging at the accessory papilla (arrowed).

the uncinata process can be missed altogether. A normal pancreatogram (of good quality, i.e. showing branches throughout the gland) has a specificity of about 95% in ruling out pancreatic cancer.

The pancreatogram is often normal in patients with recurrent attacks of acute pancreatitis. Abnormalities are classified by the Cambridge system (Table 6.1). In *marked* chronic pancreatitis, the main or branch ducts are usually diffusely and irregularly dilated (Fig. 6.70), and often contain filling defects which eventually calcify and cause duct obstruction. Without calcification,

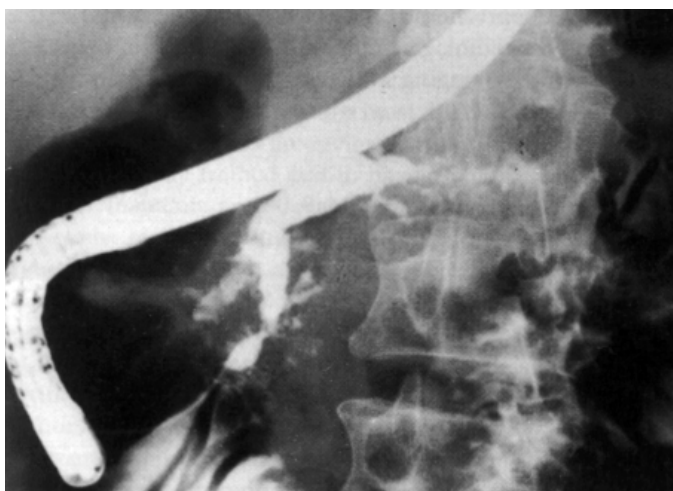


Fig. 6.70 Chronic pancreatitis with disorganization of the duct system, multiple strictures and areas of dilatation.

| Terminology | Main duct | Abnormal side branches | Additional features |
|--------------------|------------------|-------------------------------|--|
| Normal | Normal | None | |
| Equivocal | Normal | Fewer than 3 | |
| Mild | Normal | 3 or more | |
| Moderate | Abnormal | More than 3 | |
| Marked | Abnormal | More than 3 | One or more of: large cavity, obstruction filling defects, severe dilatation or irregularity |

If pathological changes are limited to one-third or less of the gland they are said to be 'local', and are designated as being in the head, body or tail; if more than one-third is affected, they are diffuse.

Table 6.1 Classification of pancreatograms in chronic pancreatitis (Cambridge system).

the radiographic appearances of duct obstruction due to pancreatitis may resemble those seen in cancer — indeed the two diseases may occasionally coexist. Radiographically, *moderate* pancreatitis is characterized by less impressive variation in the main pancreatic duct and its branches. The earliest changes in *mild* pancreatitis are seen in the branch ducts alone. The clinical significance of minor branch duct changes remains controversial, but there are correlations with functional abnormalities and clinical follow-up. However, similar abnormalities in the branch ducts can occur with advancing age. Radiographs are interpreted as ‘equivocal’ when less than three branches appear abnormal.

The ERCP report should be the combined opinion of the endoscopist and the radiologist, in the full knowledge of the clinical context and other imaging studies.

Further reading

See further reading list in Chapter 8.